

Assessment of the primary stability of root analog zirconia implants designed using cone beam computed tomography software by means of the Periotest[®] device: An ex vivo study. A preliminary report

Jacek Matys^{1, A-D}, Katarzyna Świder^{1, D}, Rafał Flieger^{2, E}, Marzena Dominiak^{3, E, F}

¹ Private Dental Practice, Wschowa, Poland

² Private Dental Practice, Kościan, Poland

³ Dental Surgery Department, Wrocław Medical University, Poland

A – research concept and design; B – collection and/or assembly of data; C – data analysis and interpretation; D – writing the article; E – critical revision of the article; F – final approval of article

Advances in Clinical and Experimental Medicine, ISSN 1899-5276 (print), ISSN 2451-2680 (online)

Adv Clin Exp Med. 2017;26(5):803–809

Address for correspondence

Jacek Matys

E-mail: jacek.matys@wp.pl

Funding sources

None declared

Conflict of interest

None declared

Received on June 19, 2016

Revised on August 20, 2016

Accepted on September 06, 2016

Abstract

Background. The implant primary stability is a fundamental prerequisite for a success of osseointegration process which determines the prosthetic reconstruction time.

Objectives. The aim of the present study was to assess the quality and precision of modern conical bone computer tomography (CBCT) software in preparing root analog zirconia implants (RAZIs) by measuring its primary stability by means of the Periotest device.

Material and methods. Thirteen pig jaws with proper erupted first premolar (P1) teeth were used in the study. The CBCT examination was conducted in the area of the P1 tooth in each mandible. The 3-dimensional (3D) view of each tooth was designed from CBCT scan. The created 3D images were used to prepare root analog zirconia implants milled from a medical-grade zirconia block by means of laboratory milling. The RAZIs and titanium implants were placed into an alveolar socket after the tooth had been removed. The primary stability of the teeth before their extraction (G1), RAZIs (G2) and titanium implants (G3) were checked by Periotest devices.

Results. The mean results in PTV were: 15.9, 3.35, 12.7 for G1, G2 and G3 group, respectively. RAZIs during immediate loading achieved a significantly higher primary stability (lower Periotest value) as compared to the teeth and implants.

Conclusions. The modern CBCT device allows us to design a precise image of an extracted tooth for the purpose of manufacturing a root analog implant. The additional feature of the surgical protocol using RAZI is the possibility of avoiding the augmentation procedure, which reduces the whole cost of the treatment.

Key words: RAZI, primary stability, root analog zirconia implant, Periotest

DOI

10.17219/acem/65069

Copyright

Copyright by Author(s)

This is an article distributed under the terms of the Creative Commons Attribution Non-Commercial License (<http://creativecommons.org/licenses/by-nc-nd/4.0/>)

The primary stability of dental implants, determined by the absence of mobility in the bone, corresponds with the mechanical coupling of an implant with the surrounding bone tissue promptly after implant insertion and represents a fundamental prerequisite for osseointegration.^{1,2} Poor primary stability results in the formation of fibrous tissues in the interface between the implant and the bone, inducing bone resorption, which is one of the principal reasons for the implant failure.³ Brunski claims that excessive loads and micromotion may disrupt the process of osteogenesis and endanger implantation success.³ The development of traditional late-loaded implants in recent years has contributed to fewer problems with regard to primary stability and implant osseointegration.⁴ Clinical studies including over 5 years of implant case studies show that 99.1% of implants in the mandible and 84.9% in maxilla undergo osseointegration, which is a part of a fully functional prosthetic reconstruction.⁴

Nevertheless, the situation differs in relation to immediate implantation. Immediate implant placement involves the insertion of implants immediately after surgical extraction of the teeth to be replaced.² This approach has several advantages, such as the preservation of the alveolar width and height, reduction of bone resorption and limitation of soft tissue trauma, decrease in the treatment time and avoidance of a second surgical intervention, resulting in cost reduction and improvement of patients' comfort.^{2,5-7} However, one of the most important drawbacks related to immediate implant placement is the difficulty in achieving primary stability.²

In order to provide sufficient primary stability in immediate or early loaded implants, researchers tried to compile different implantation systems.^{5,6,8-11} Hodosh et al. were the first to propose an alternative to the traditional implant systems, i.e. the fabrication of a customized, dental root analog implant (RAI) using polymethacrylate.⁶ However, the use of the preceding material caused the root analog to become encapsulated by soft tissue.⁸ Therefore, root analog zirconia implants (RAZIs) and root analog titanium implants (RATIs) are being suggested for usage.^{5,8} Both types of analogs are closely fitted to the socket but RATI has shown some disadvantages in clinical use.⁸ Experimental studies with RATI have yielded successful results with evidence of osseointegration and clinical stability.^{6,9} The clinical trial of a 1-month follow-up resulted in 100% primary stability at insertion, but after 9 months this implant system acquired the failure rate of 48%.¹⁰

In order to assure the implantation success, the researchers developed a novel approach to fabricate a zirconia dental root analogue implant (RAZI) using cone beam computed tomography (CBCT) scan and computer aided designing (CAD)/computer aided manufacturing (CAM) technologies.⁸ With those two combined techniques it is possible to manufacture a RAZI with the best primary

stability.⁸ The combination of CBCT and CAD/CAM enables the fabrication of RAZIs as the perfect copies of the radicular units needed for implantation.⁸

The primary stability of RAZI designed using CBCT scan and CAD/CAM technologies can be measured by a variety of techniques, including: cutting resistance analysis (CRA), reverse torque test (RTT), resonance frequency analysis (RFA), impact hammer method.¹²⁻²⁴

In the cutting resistance analysis (CRA) a torque gauge incorporated within the drilling unit is used to determine the implant insertion torque and to measure bone quality in various parts of a jaw.¹³ The energy required for a current-fed electric motor to cut the bone during implant surgery is measured. This energy was shown to be significantly correlated with bone density and thus determined poor-quality bone, which has been suggested as one of the factors that significantly influences implant stability.¹⁴ The major drawback of this technique is that it does not provide any information regarding bone quality until an osteotomy is performed.¹⁵ Also, CRA cannot identify the lower limit of cutting torque value at which the implantation would end in failure.¹⁵

The resonance frequency analysis (RFA) is an electronic method for testing implant stability and was developed by Meredith et al.¹⁶ RFA can be used to monitor the changes in stiffness and stability at the implant – tissue interface and to discriminate between successful implants and clinical failures.^{17,18} Meredith et al. suggested that this test be executed at the implant placement as a basic reading for future comparison.¹⁶ However, it is tricky to characterize a general standardized range of ISQ readings for a successful implant osseointegration for different implant systems.¹⁹

The reverse torque test (RTT) was first proposed by Roberts et al. and measures the crucial torque threshold, where bone-implant contact (BIC) was destroyed.²⁰ Nevertheless, this technique has been criticized as being destructive and it provides only information as to “all or none” outcome (osseointegrated or failed); thus, it cannot quantify the degree of osseointegration. Hence, RTT is mainly used in experiments.²¹

The impact hammer method incorporates the sound generated from a contact between a hammer and an object. The response detection is enhanced by various devices (microphone, accelerometer, strain gauge) and analyzed through fast fourier transform (FFT) in the form of physical properties.²² This method is used in Periotest (Seimens, AG, Bensheim, Germany) and Dental mobility checker® (DMC).²¹ The difference between the two is that DMC applies impact force with a hammer while the Periotest uses a metallic tapping rod in a handpiece, which is electromagnetically driven and electronically controlled. In the Periotest, response to striking is measured by an accelerometer and then analyzed. The signals produced by tapping are then converted to a unique value called the Periotest value (PTV), which depends

Fig. 1. The procedure of preparing the STL file of a tooth from a CBCT scan

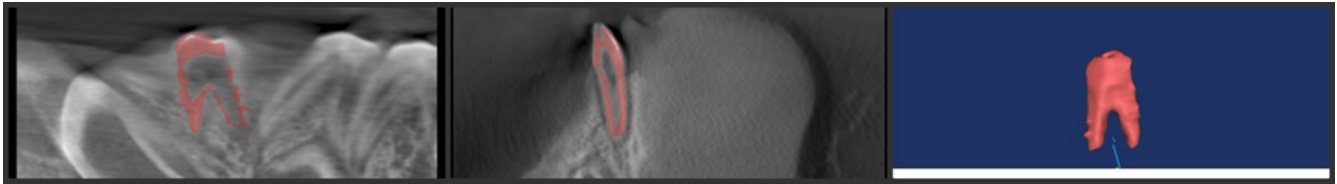
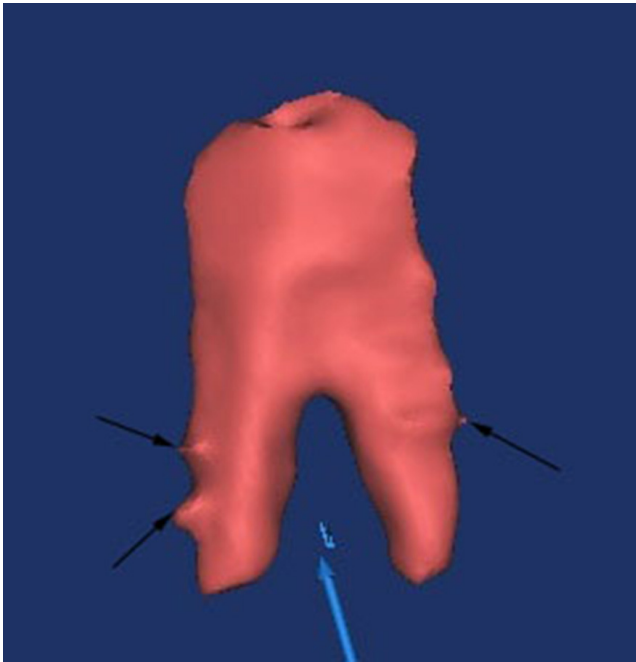


Fig. 2. The 3D view of a tooth. The blue arrow indicates a tooth and black arrows show macro-retentions of the tooth surface



on the damping characteristics of tissues surrounding teeth or implants.²⁴ According to Dilek et al., immediate loading can only occur if their PTV is in the range of $-8-(+9)$, whereas Atsumi et al. narrowed the range to $-4-(-2)$ and $-4-(+2)$.^{21,24}

The aim of the present study was to prove better primary implant stability during immediate placement of the root analog zirconia implants (RAZIs) in comparison to traditional tapered screw implant systems, on the basis of the Periotest values. RAZIs were constructed using the modern cone beam computed tomography (CBCT) scan and 3-dimensional (3D) root surface models.

Material and methods

Samples preparation

The research included 13 mandibles ($n = 13$) of recently slaughtered pigs, breed: *Złotnicka Biała*, intended for consumption and which had been obtained from a butcher. The specimens were included in the study due to the proper eruption of a first premolar (P1) tooth in

the mandible, then each mandible had been prepared by the front incisors region being cut, washed under tap water and left for 4 h before the research was commenced. The specimens after preparation were placed motionless in a clamp. Ethical approval was not required for this animal ex vivo study.

Design procedure

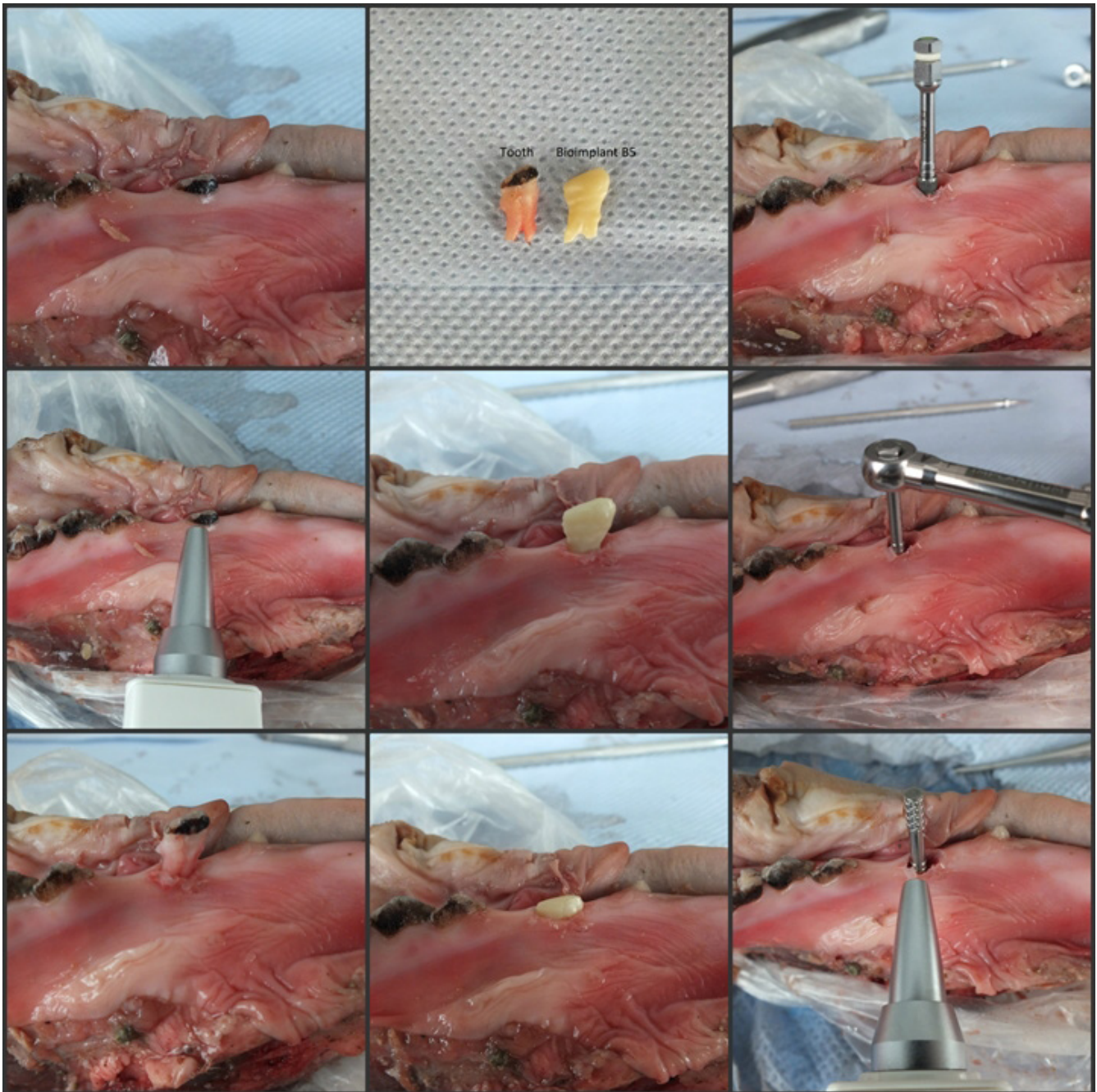
The position of the 1st premolar tooth of each specimen was controlled by conical bone computer tomography (CBCT) examination (Kodak 9000 3D, Carestream/Trophy, Marne-la-Vallée, France), with a field of view (FOV) equal 5×4 cm, nominal beam of 73 kV, 12 mA and a voxel size of $90 \mu\text{m}$. The 3-dimensional (3D) view of each tooth was designed from CBCT scan by means of computer tomography (CT) software (Mimics, Materialize, Leuven, Belgium) (Fig. 1). The image of the tooth was manually separated in each slice of a conical bone computer tomography by the same operator (J.M.). Next, the surface of the tooth in CBCT was modified to better fit the alveolar socket by remodeling its surface. The macro-retentions were designed only onto mesial and distal part of the root according to the study protocol. The macro-retentions strictly limited to the interdental space, and the buccal and lingual faces were reduced by 0.1–0.2 mm according to Pirker's protocol (Fig. 2).

The created 3D images were exported to STL (Stereo Lithography) file format and were used to prepare a root analog zirconia implants milled from a medical-grade zirconia block by means of a laboratory milling (DMG Sauer Ultrasonic 20, USA). Next, the RAZI was sintered for 8 h to achieve the desired mechanical properties.

Surgical procedure

After the tooth had been cautiously removed with the use of the Periotome instrument, the RAZI was placed into the alveolar socket under finger pressure and then gently tapped with a hammer and a mallet. Next, RAZI was removed and a titanium implant (Superline, Dentium, Korea), 4.0 mm in diameter and 10 mm in length was placed manually using a ratchet, subcrestally into the socket according to factory surgical protocol. The parallel pin was screwed to the implant to control the implant primary stability.

Fig. 3. The surgical protocol and measurement procedure used in the study



Measurement procedure and study design

The primary stability coupled with the Periotest test value (PTV) was measured by means of the Periotest device (Medzintechnik Gulden e K, Modautal, Germany). In practice, the Periotest test values (PTVs) are based on a numerical scale ranging from -8 to +50, determined by mathematical calculations. The lower Periotest values denote higher implant stability and thereby the higher damping effect of the target tissues.

The measurement of PTV was carried out on the tooth before its extraction (G1 group), next on the RAZI, which

was placed in the alveolar socket (G2 group), and on the screw titanium implant (G3 group) placed subcrestally in the socket after RAZI removal (Fig. 3).

Statistical analysis

To assess whether the data was normally distributed, the Kolmogorov-Smirnov test was performed at the 95% level. The statistical analysis was performed by means of a one-way ANOVA test with the use of the STATISTICA v. 12 program (StatSoft, Kraków, Poland). Pair comparisons were carried out based on the Tukey post hoc test at significance levels of $p = 0.05$.

Results

An analysis of the primary stability revealed significant differences in PTV results for G2 (RAZIs) as compared to G1 and G3 groups (Table 1). Our findings show that a mean PTV value measured for RAZIs was 4.7 times and 3.8 times lower as compared to the teeth and screw implants, respectively. The lower PTV value means that the primary stability of root analog zirconia implants was significantly higher in comparison with the teeth and the screw implants.

The analysis of the PTV value of the teeth (G1) revealed higher results (lower primary stability) than in the cases when a screw implants (G3) were used. However, there was no significant increase in PTV results when compared this 2 groups (Fig. 4).

Discussion

The use of digital technology in dentistry is becoming more common and presents many advantages. Firstly, due to the CT/CBCT scan banks, the surgical procedure is marked by reduced treatment time and an immediate

restoration – whole surgery can end in one initial dental visit, whereas conventional implants take at least 2–3 visits. Thanks to CBCT scans, the root replica is obtained prior to tooth extraction. Therefore, there is no need for subsequent surgery, as the tooth extraction and RAI implantation can take place during the same visit. Other benefits include increased patient comfort as well as better esthetics due to mimicking root features.⁸

The results of research of Moin and Al-Rawi proved the increase in surface details of the 3D surface model compared to the original tooth.^{5,25} Through CAD/CAM designing many alterations (macroretentions, corrections of the shape) can be added to the RAI. It is also possible to pre-operatively design the abutment form or temporary crown.⁸

Furthermore, Chahine et al. presented many advantages of RAI (specifically RATI) in comparison to the traditional implantation methods.²⁶ RAI is adjusted to the particular patient’s clinical situation, thereby permitting excellent reconstruction of function and esthetics. Since the damaged tooth is extracted using atraumatic methods, the implantation takes almost no site preparation, resulting in enhanced bone response and faster healing. Apart from the aforementioned benefits of RAI, Chahine et al. also list improved bite feel (thanks to micromotion means), patient satisfaction and quality of life, and also reduced treatment cost.²⁶

Moin et al. in another study assessed the accuracy of the individually fabricated RAI based on CBCT scan, computer-aided designing (CAD), and computer-aided manufacturing (CAM) technology and measured the discrepancy in congruence with the alveolar socket subsequent to placement of the RAI.²⁷ The authors showed that the volume of the socket was greater than the root part of the RAI ranging from 0.6% to 5.9%. These results confirmed that preparing macroretentions on the RAI’s surface is a key factor in achieving proper initial stabilization of the RAI.

Though RATI presented excellent primary stability sustained up to 1 month, it also showed a failure rate of 48% at a 9-month and 97% at a 1-year follow-up.¹⁰ Therefore, some authors prefer using RAZI instead of RATI.²⁸

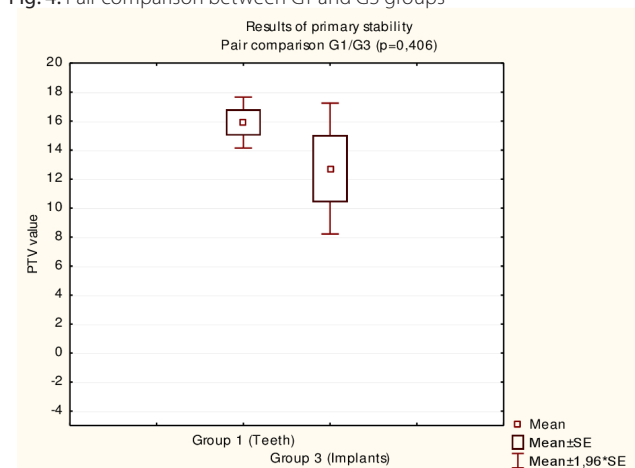
Chen et al. in their research assessed the root analog titanium implants (RATI) and the primary stability and stress distribution in the bone of root analog threaded titanium implants (RATTI).²⁹ The root analog titanium implants were printed in 3 dimensions (3D) with the selective laser melting technique. The results of their research indicated that better initial stability was obtained with a RATI. The maximum stress between the cortical bone and RATTI interfaces was 41.8%, lower than that of the RATI under immediate loading.²⁹ Hence, the RATTI design should have an advantage over the conventional RATI because of the beneficial stress distribution in the early stages of healing. The stress in the cortical bone can be reduced by customizing the RAI surface.²⁹ Pirker et al. proposed to reduce the buccal and lingual face of the root analog im-

Table 1. The mean PTV’s values and standard deviation in G1, G2, G3 groups. There were significant differences in PTV results between groups G2 and G1, G2 and G3)

Study groups	Mean PTV	N	SD
G1 (teeth)	15.9000	13	3.2326
G2 (RAZI)	3.3538	13	6.1371
G3 (implants)	12.7231	13	8.3012
All groups	10.6589	39	8.1281

G2 vs G1 p = 0.000151; G2 vs G3 p = 0.00152; PTV – periost test value; SD – standard deviation; N – number of cases.

Fig. 4. Pair comparison between G1 and G3 groups



plant by 0.1–0.2 mm to diminish stress in the cortical bone and to avoid fracture of the thin alveolar bone wall.²⁸

Pirker et al. state better esthetics (no metallic elements showing through the mucosa), enhanced mechanical (high flexural strength, hardness, fracture toughness, high electrical resistance) and chemical properties (superior plaque resistance) of RAZI.²⁸ A rough root surface topography (micro- and macroretentions) speeds up the osseointegration process. Its excellent biocompatibility is similar to that of titanium implants, which has been demonstrated in several animal investigations.³⁰

In the presented study, RAZI was modified according to the Pirker's protocol.²⁸ The macroretentions were limited only to the interdental space (mesial and distal part of the root) for better primary stability and osseointegration. The buccal and lingual faces were reduced by 0.1–0.2 mm to avoid fracture and bone loss. Moreover, since achieving primary implant stability includes the conservation of the alveolar socket walls, the teeth were extracted using atraumatic techniques. Furthermore, the RAZI fabrication was performed using cone beam computed tomography (CBCT) scan technology of the socket and tooth before the extraction. Fabrication of RAZI may be carried out also by scanning the extracted tooth using the laser scanner.²⁸ Nevertheless, using just the laser scanner has some disadvantages. If the tooth is damaged before or during the extraction, it becomes difficult to put it together and scan.⁸ The implantation is postponed until the dental laboratory prepares the RAZI. Also, the alveolar socket needs to be curetted again before the implantation.²⁸ CBCT method allows to perform the procedure despite above drawbacks and immediately, since the RAZI is prepared before the extraction.⁸

The presented study showed better values of PTV for RAZI in comparison to the titanium implants and natural teeth. According to Dilek et al., immediate loading can only occur if their PTV is in the range between -8 to +9, whereas Atsumi et al. narrowed the range to -4–(-2) and -4–(+2).^{21,24} However, research conducted by Dilek et al. involved mini-implants; therefore, the range of PTV was more extensive.²⁴ The results of PTV in this study amounted to an average of 3.35, which means that they are the closest to the values that enable primary stability and immediate implantation of RAZI compared to two mentioned studies.

Further studies should be conducted to assess the impact of different macroretentions applied through CAD/CAM method at the root surface on the primary stability of RAZI.

Conclusion

The modern CBCT device allows us to design precise images of an extracted tooth for the purpose of developing a root analog implant. Within the limitations of the present ex vivo study, it is evident that the root analog

zirconia implants during immediate loading achieved a good implant primary stability. The additional feature of the surgical protocol using RAZI is the possibility to avoid the augmentation procedure, which reduces the whole cost of the treatment.

References:

- Natali AN, Carniel EL, Pavan PG. Investigation of viscoelastoplastic response of bone tissue in oral implant stress fit process. *J Biomed Mater Res B Appl Biomater*. 2009;91:868–875.
- Koh R, Rudek I, Wang HL. Immediate implant placement, positives and negatives. *Implant Dent*. 2010;19:98–108.
- Brunski JB, Puleo DA, Nanci A. Biomaterials and biomechanics of oral and maxillofacial implants: Current status and future developments. *Int J Oral Maxillofac Implants*. 2000;15:15–46.
- Binahmed A, Stoykewych A, Hussain A. Long-term follow-up of hydroxyapatite-coated dental implants: A clinical trial. *Int J Oral Maxillofac Implants*. 2007;22(6):963–968.
- Regish KM, Sharma D, Prithviraj DR. An overview of immediate root analogue zirconia implants. *J Oral Implantol*. 2013;39:225–233.
- Singh M, Kumar L, Anwar M, Chand P. Immediate dental implant placement with immediate loading following extraction of natural teeth. *Nat J Maxillofac Surg*. 2015;6(2):252.
- Kazor CE, Al Shamari K, Sarment DP, Misch CE, Wang HL. Implant plastic surgery, a review and rationale. *J Oral Implantol*. 2004;30:240–254.
- Moin DA, Hassan B, Mercelis P, Wismeijer D. Designing a novel dental root analogue implant using cone beam computed tomography and CAD/CAM technology. *Clin Oral Implants Res*. 2013;24:25–27.
- Kohal RJ, Hürzeler MB, Mota LF, Klaus G, Caffesse RG, Strub JR. Custom-made root analogue titanium implants placed into extraction sockets: An experimental study in monkeys. *Clin Oral Implants Res*. 1997;8:386–392.
- Kohal RJ, Klaus G, Strub JR. Clinical investigation of a new dental immediate implant system. The Reimplant®-System. *Deutsch Zahnarz Zeit*. 2002;57:495–497.
- Singh A, Gupta A, Yadav A, Chaturvedi TP, Bhatnagar A, Singh BP. Immediate placement of implant in fresh extraction socket with early loading. *Contemp Clin Dent*. 2012;3(Suppl 2):219–222.
- Mall N, Dhanasekar B, Aparna IN. Validation of implant stability: A measure of implant permanence. *Indian J Dent Res*. 2011;22:462–67.
- O'Sullivan D, Sennerby L, Jagger D, Meredith N. A comparison of two methods of enhancing implant primary stability. *Clin Implant Dent Relat Res*. 2004;6:48–57.
- Friberg B, Sennerby L, Meredith N, Lekholm U. A comparison between cutting torque and resonance frequency measurements of maxillary implants: A 20-month clinical study. *Int J Oral Maxillofac Surg*. 1999;28:297–303.
- Friberg B, Sennerby L, Grondahl K, Bergstrom C, Back T, Lekholm U. On cutting torque measurements during implant placement: A 3-year clinical prospective study. *Clin Implant Dent Relat Res*. 1999;1:75–83.
- Meredith N, Alleyne D, Cawley P. Quantitative determination of the stability of the implant-tissue interface using resonance frequency analysis. *Clin Oral Implants Res*. 1996;7:261–267.
- Zix J, Hug S, Kessler-Liechti G, Mericske-Stern R. Measurement of dental implant stability by resonance frequency analysis and damping capacity assessment, comparison of both techniques in a clinical trial. *Int J Oral Maxillofac Implants*. 2008;23:525–530.
- Sjöström M, Lundgren S, Nilson H, Sennerby L. Monitoring of implant stability in grafted bone using resonance frequency analysis: A clinical study from implant placement to 6 months of loading. *Int J Oral Maxillofac Surg*. 2005;34:45–51.
- Ersanli S, Karabuda C, Beck F, Leblebicioglu B. Resonance frequency analysis of one-stage dental implant stability during the osseointegration period. *J Periodontol*. 2005;76:1066–1071.
- Roberts WE, Smith RK, Zilberman Y, Mozsary PG, Smith RS. Osseous adaptation to continuous loading of rigid endosseous implants. *Am J Orthod*. 1984;86:95–111.

21. Atsumi M, Park SH, Wang HL. Methods used to assess implant stability: Current status. *Int J Oral Maxillofac Implants*. 2007;22:743–754.
22. Meredith N. Assessment of implant stability as a prognostic determinant. *Int J Prosthodont*. 1998;11:491–501.
23. Schulte W, Lukas D. The periostest method. *Int Dent J*. 1992;42:433–440.
24. Dilek O, Tezulas E, Dincel M. Required minimum primary stability and torque values for immediate loading of mini dental implants: An experimental study in nonviable bovine femoral bone. *Oral Surg Oral Med Oral Pathol Oral Radiol Endod*. 2008;105:20–27.
25. Al-Rawi B, Hassan B, Vandenberghe B, Jacobs R. Accuracy assessment of three-dimensional surface reconstructions of teeth from cone beam computed tomography scans. *J Oral Rehab*. 2010;37:352–358.
26. Chahine G, Smith P, Kovacevic R, Ajlouni R, Ajlouni K. Digital engineering of bio-adaptable dental implants. In: Turkyilmaz I, ed. *Implant dentistry: A rapidly evolving practise*. InTech. 2011:251–266.
27. Moin DA, Hassan B, Parsa A, Mercelis P, Wismeijer D. Accuracy of preemptively constructed, cone beam CT-, and CAD/CAM technology-based, individual root analogue implant technique: An in vitro pilot investigation. *Clin Oral Implants Res*. 2014;25(5):598–602.
28. Pirker W, Wiedemann D, Lidauer A, Kocher AA. Immediate, single stage, truly anatomic zirconia implant in lower molar replacement: A case report with 2.5 years follow-up. *Int J Oral Maxillofac Surg*. 2011;40:212–216.
29. Chen J, Zhang Z, Chen X, Zhang C, Zhang G, Xu Z. Design and manufacture of customized dental implants by using reverse engineering and selective laser melting technology. *J Prosthet Dent*. 2014;112(5):1088–1095.
30. Depprich R, Zipprich H, Ommerborn M, et al. Osseointegration of zirconia implants compared with titanium: An in vivo study. *Head Face Med*. 2008;4:30.