

RAFAŁ FLIEGER^{1, A-D}, PRZEMYSŁAW KOPCZYŃSKI^{1, D}, TERESA MATTHEWS-BRZOZOWSKA^{2, D, E, F}

Analysis of Skeletal Maturity of Children with Cleft Palate in Terms of Healthy Children by the CVM Method

¹ Centre for Orthodontic Mini-implants at the Department and Clinic of Maxillofacial Orthopaedics and Orthodontics, Poznan University of Medical Sciences, Poland

² Department of Orthodontics, Poznan University of Medical Sciences, Poland

A – research concept and design; B – collection and/or assembly of data; C – data analysis and interpretation; D – writing the article; E – critical revision of the article; F – final approval of article; G – other

Abstract

Background. For many years, the analysis of bone age X-rays have been used for the hand and wrist, which were assessed on the basis of changes in the various centers of ossification. These images, however, do not constitute a diagnostic element of cleft defects, leading to additional exposure of the patient to X-rays. The problem was solved by using lateral head films, which enabled the interpretation of the morphological changes in the cervical spine to evaluate skeletal development stages.

Objectives. The objective of this work is to define the differences between the skeletal age and chronological age of children with malocclusion and congenital craniofacial disorders – primary and secondary palate cleft.

Material and Methods. The study material comprised 90 lateral cephalometric radiographs of patients at the age of 7 to 16 (45 lateral head radiographs of patients with various occlusion disorders and 45 lateral head radiographs of patients with various types of primary and secondary palate cleft). Then, all the lateral cephalometric radiographs were analysed in terms of the shape of the 2nd, 3rd and 4th cervical vertebra in line with the Cervical Stage method (CS), developed by Baccetti et al. in 2005.

Results. Patients with malocclusions without malformations achieved various stages of bone development at an earlier chronological age compared with patients with primary and secondary palate. An exception was the phase CS 3 (early growth spurt) development disorders, in which patients with different types of cleft had lower chronological age compared with patients with malocclusion.

Conclusions. The method that allows for an assessment of the development of skeletal maturity is the analysis of the shape of the cervical vertebrae in lateral head film (*Adv Clin Exp Med* 2015, 24, 1, 99–102).

Key words: skeletal age, CVM method, palate cleft.

The cervical vertebrae analysis is a method that allows us to assess skeletal maturation and shows a very high potential in defining the patient's bone age. In 1972, Lamparski, in the course of his cervical vertebrae development studies, described an effective method of defining the skeletal maturity of the cervical vertebrae, i.e. cervical vertebrae maturation, and identified 6 stages of skeletal maturity characteristic for subsequent stages of maturation [1]. In 1995, Hassel and Farman discovered that using a thyroid protective collar when taking lateral cephalometric radiographs restricts the full view of the cervical spine. Therefore, they developed a new CVM index which evaluated only 3 vertebrae: C2, C3 and C4. The authors found that

changes in the shape of the vertebrae (concavity of the inferior border and height) may be helpful in defining the bone age and predicting the growth potential [2]. Franchi et al. modified that method and named it CS – cervical stage.

CS 1 – inferior borders of the C2 and C3 bodies are flat, C 3 and C 4 are trapezoidal – the peak in mandibular growth will occur in 2 years.

CS 2 – concavity appears at the inferior border of the C2 body, C2 and C3 are trapezoid in shape – the peak in mandibular growth will occur in a year.

CS 3 – concavities are present at the inferior borders of C2 and C3 bodies, the C2 and C3 bodies are rectangular horizontal in shape – the peak in mandibular growth will last over the next year.

CS 4 – concavities are present at all of the lower borders of C2, C3 and C4 bodies; C3 and C4 are rectangular horizontal in shape – the peak in mandibular growth occurred 1–2 years before that stage.

CS 5 – concavities are present at the C2, C3 and C4 bodies; C3 or C4 is square in shape – the peak in mandibular growth ended a year before that stage.

CS 6 – concavities at the C2, C3 and C4 bodies are evident; C3 or C4 is rectangular horizontal in shape – the peak in mandibular growth ended two years before that stage [3].

The ability to correctly predict the peak mandibular growth and, therefore, the growth potential of the mandible, is a vital factor allowing us to take effective actions related to a relevant treatment protocol, e.g. of patients with craniofacial cleft disorders [4]. The libraries lack the publications comparing the skeletal age of children with malocclusion with the skeletal age of children with primary and secondary palate clefts.

Objectives

The objective of this work is to define the differences between the skeletal age and chronological age of children with malocclusions and congenital craniofacial disorders – primary and secondary palate cleft.

Material and Methods

The study material comprised 90 lateral cephalometric radiographs of patients at the age of 7 to 16 (45 lateral head radiographs of patients with various occlusion disorders and 45 lateral head radiographs of patients with various types of primary and secondary palate cleft). Then, all the lateral cephalometric radiographs were analysed in terms of the shape of the 2nd, 3rd and 4th cervical vertebra in line with the Cervical Stage method (CS), developed by Baccetti et al. in 2005.

To examine the shape of C2, C3 and C4 in detail, reference lines and points have been set (Fig. 1). Reference points and lines for C2, C3 and C4:

C2p is the most posterior point on the lower border of C2.

C2m and C2a are respectively: the deepest and the most anterior point on the lower border of C2.

C3up and C3ua are the most superior points on the posterior and anterior border of C3.

C3lp, C3m and C3la are the most posterior, the deepest and the most anterior points on the lower border of C3.

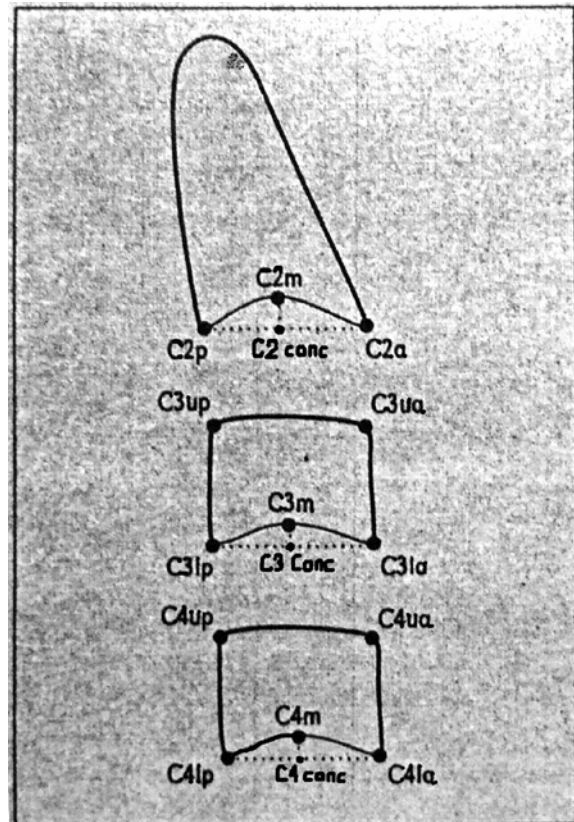


Fig. 1. Diagram reference points and lines designated circles C2, C3, and C4

C4up and C4ua are the most superior points on the anterior and posterior border of C4.

C4lp and C4la are the most posterior and anterior points on the lower border of C4; C4m is the deepest point.

C2 Conc specifies the depth of the concavity in the lower border of C2. It is the distance from the line connecting C2p and C2a to C2m.

C3 Conc specifies the depth of the concavity in the lower border of C3. It is the distance from the line connecting C3lp and C3la to C3m.

C4 Conc specifies the depth of the concavity in the lower border of C4. It is the distance from the line connecting C4lp and C4la to C4m.

Based on the points marked, subsequent parameters have been defined:

- C3PAR is the ratio between the height of the posterior and anterior border of the C3 body.

- C3BAR is the ratio between the C3 base and its anterior height.

- C4PAR is the ratio between the posterior and anterior height of C4.

- C4BAR is the ratio between the length of the base and the height of the anterior border of C4.

Statistical analyses were conducted in the Department of Bioinformatics and Computational Biology, Chair of Clinical Pathomorphology of the Poznan University of Medical Sciences. The chronological age of the patients was first verified

by means of the Shapiro-Wilk test for consistency with the normal distribution (consistency was confirmed). Therefore, parametrical statistical methods were used to carry out the statistical analysis. Average values and standard deviations were calculated for all the results.

The correlations between the chronological age were analysed in sub-groups by 3 Angle's classes, with the use of the Pearson's linear correlation coefficient. The correlations between the chronological age were also analysed in sub-groups by the cleft type (left-side, right-side and bilateral), taking into account the sex of the patient. The results concerning the average chronological age of the patients by Angle's classes and in certain skeletal age (CS1, CS2, CS3, CS4) were compared between the groups I and II by means of the Student's *t*-test for independent groups. It was assumed that the results were statistically significant if $p < 0.05$.

All the statistical calculations were conducted in STATISTICA v. 9. 0.

Results

Based on the analysis of 45 lateral cephalometric radiographs of patients with no developmental disorders, it was found that 16 patients in the average age of 11 years and 1 month were in stage CS3, 9 patients in the average age of 12 years and 9 months were in stage CS5 and 2 patients in the average age of 14 years and 5 months were in stage CS6.

Among 45 analysed lateral cephalometric radiographs of the patients with primary and secondary palate clefts, 12 patients in the average age of 10 years and 4 months were in stage CS3 and 6 patients in the average age of 14 years and 2 months were in stage CS5. No stage CS6 of the skeletal development was recorded in any of the patients with primary and secondary palate cleft. A statistically

Table 1. Chronological age of the patients with no craniofacial developmental disorders with regard to the skeletal development stage

CS	N	Mediana	SD
CS1	7	8.8	2.0
CS2	2	9.3	0.4
CS3	16	11.1	1.3
CS4	9	12.8	1.5
CS5	9	12.9	0.9
CS6	2	14.5	0.7
Total	45	11.5	21

CS1 vs CS4 – $p < 0.003$; CS1 vs CS5 – $p < 0.002$

Table 2. Chronological age of the patients with primary and secondary palate clefts with regard to the skeletal development stage

CS	N	Mediana	SD
CS1	8	9.4	2.2
CS2	10	10.2	1.6
CS3	12	10.4	1.3
CS4	9	13.6	1.3
CS5	6	14.2	1.2
CS6	0		

CS1 vs CS4 – $p < 0.004$; CS1 vs CS5 – $p < 0.002$

CS2 vs CS4 – $p < 0.02$; CS2 vs CS5 – $p < 0.001$

CS3 vs CS4 – $p < 0.02$; CS3 vs CS5 – $p < 0.01$

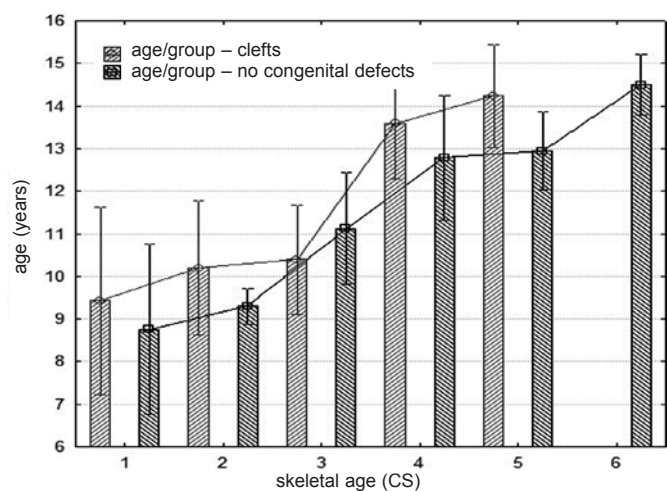


Fig. 2. Graphical juxtaposition of bone age compared with chronological age of patients with primary and secondary cleft palate, and patients without congenital malformations of the craniofacial

significant difference was recorded as regards the average age of stage CS5 in both analysed groups

Patients with no developmental disorders went through specific stages of skeletal development at an earlier chronological age than the patients with primary and secondary palate clefts. Stage CS3 (beginning of the peak mandibular growth) was an exception as patients with various cleft types achieved that stage at an earlier chronological age than the patients with malocclusion.

Discussion

The conducted study indicates differences between the skeletal age and chronological age in the examined patients. It should be underlined that the skeletal age is part of the biological age assessment. Development appraisal methods comprise, among others: standards tables as biological

reference systems, percentile grids, proportion indices, e.g. Quetelet's index, BMI index, morphograms, body composition indices including LBM (Lean Body Mass), BIA (Biological Impedance Analysis), biochemical indices of development, e.g. hydroxyproline, and biological age assessment covering the skeletal age and development of sexual traits [5]. The authors found the chronological age to be the least accurate manner to assess the peak growth. On the other hand, the appearance of the secondary sexual traits, analysis of the degree of teeth mineralisation and eruption timing, as well as bone age determination can be used as reference points in the assessment of the peak growth.

For many years, hand and wrist X-rays were used to appraise the changes occurring in specific ossification centres and to determine the skeletal age. The results were interpreted according to the existing atlases, which allowed for the final determination of a patient's skeletal development. However, such X-rays were not a part of the cleft disorder diagnosis and exposed the patient to additional radiation. The problem was solved by using lateral cephalometric radiographs which allowed us to examine the morphological changes in cervical vertebrae in order to assess the skeletal age. The decision was justified, among others, by the fact that lateral cephalometric radiographs are a standard procedure in performing cephalometric analyses, which, in turn, were vital for accurate orthodontic diagnostics [6]. It is essential to position the patient in the right manner when taking the radiograph. Currently, digital head-positioning devices are most popularly used. The patient's position during such radiographs is determined by means of a laser beam, which allows for

accurate positioning of the head in relation to the middle plane (to obtain a uniform image) and to the horizontal plane (to obtain the correct head tilt angle) [7].

The lateral cephalometric radiographs analysed in the study were taken by means of the traditional method with an X-ray plate. The quality of the photos was satisfactory and in each case allowed to determine the patients' skeletal age based on the visual examination of the cervical vertebrae from C2 to C4 with the use of the method proposed by Franchie et al.

The conducted analyses allowed us to identify differences in the skeletal age (determined with the CVM method) between healthy children and children with congenital craniofacial disorders (primary and secondary palate cleft). No such differences were found between boys and girls without developmental disorders as well as between boys and girls with congenital craniofacial disorders (primary and secondary palate cleft). The appraisal of the shape of cervical vertebrae in lateral cephalometric radiographs allowed us to determine the skeletal age in children with congenital craniofacial disorders as well as in children without such disorders. Based on the estimated skeletal age of children with malocclusion and children with malocclusion and developmental disorders, it has been proved that there are considerable differences between the skeletal age and chronological age. As regards the relation between the chronological age and the stages of skeletal development, the difference between children with congenital craniofacial disorders and children without such disorders amounts to ca. 1 year. In patients with primary and secondary palate clefts, the analysis of the skeletal age showed that the peak growth usually ends at an average age of 14.

References

- [1] **Gandini P, Mancini M, Andreanic F:** A comparison of hand-wrist bone and cervical vertebral analyses in measuring skeletal maturation. *Angle Orthod* 2006, 76, 984–989.
- [2] **Hassel B, Farman:** Skeletal maturation evaluation using cervical vertebrae. *Am J Orthod Dentofacial Orthop* 1995, 107, 58–66.
- [3] **Franchi L, Baccetti T, McNamara JA Jr:** Man-dibular growth as related to cervical vertebral maturation and body height. *Am J Orthod Dentofacial Orthop* 2000, 11, 335–340.
- [4] **Sato K, Mito T, Mitani H:** An accurate method of predicting mandibular growth potential based on bone maturity. *Am J Orthod Dentofacial Orthop* 2001, 120, 286–293.
- [5] **Krawczyński M:** Metody oceny rozwoju fizycznego – wykorzystywane w praktyce poradnianej. *Przew Lek* 2001, 4, 92–96.
- [6] **Damian MF, Cechinato F, Molina RD, Woi-tchunas FE:** Relationship between cranial and mandibular growth and the stages of maturation of the cervical vertebrae. *J Appl Oral Sci* 2007, 15, 115–119.
- [7] **Mahajdan S:** Evaluation of skeletal maturation by comparing the hand wrist radiograph and cervical vertebrae as seen in lateral cephalogram. *Indian J Dent Res* 2011, 22, 309–316.

Address for correspondence:

Rafał Flieger
Poznań
Bukowska 70
Tel.: +48 660 446 872
E-mail: gabinet6@op.pl

Conflict of interest: None declared

Received: 27.08.2013

Revised: 23.04.2014

Accepted: 12.01.2015