

HAYRETTIN OZTURK¹, KAZIM KARAASLAN², HASAN KOCOGLU²

Use of Glubran 2 Surgical Glue in Circumcision Results in a Comfortable Postoperative Period

Zastosowanie kleju chirurgicznego Glubran 2 w zabiegach obrzezania a okres pooperacyjny

Departments of Pediatric Surgery¹ and Anesthesiology², Medical School, Abant Izzet Baysal University, Bolu, Turkey

Abstract

Objectives. The aim of this study was to evaluate the effects of Glubran 2 on bleeding, wound healing, and patient comfort in the postoperative period together with its effectiveness in approximating the skin edges in circumcision.

Material and Methods: A total of 247 patients (age range: 1–12 years) underwent circumcision using a suture for wound approximation (group 1, n = 57) or circumcision using Glubran 2 surgical glue after subcuticular skin closure (group 2, n = 190). The circumcision was performed using a sleeve technique. All patients received standard general anesthesia and caudal blockade with levobupivacaine was applied after anesthesia induction. In group 2, after meticulous hemostasis, the incision was cleansed and the skin edges were approximated in a subcuticular manner. A thin layer of Glubran 2 surgical glue was applied and allowed to dry. Antibiotic ointment was then applied to the glans and penis.

Results. There were no significant differences between the two groups regarding wound inflammation, wound infection, bleeding, wound dehiscence, and edema. However, the cosmetic outcomes and parental satisfaction were consistently greater in group 2.

Conclusions. After approximating the edges subcuticularly after skin closure, using Glubran 2 surgical glue is a safe, comfortable, and cosmetically appealing method in circumcision (*Adv Clin Exp Med* 2009, 18, 4, 381–384).

Key words: circumcision, tissue glue.

Streszczenie

Cel pracy. Ocena skuteczności kleju Glubran 2 zastosowanego podczas zabiegu obrzezania.

Materiał i metody. 247 pacjentów (wiek 1–12 lat) poddano zabiegowi obrzezania, w tym z użyciem szwu do zbliżenia rany (grupa 1, n = 57) i z zastosowaniem kleju chirurgicznego Glubran 2 po zamknięciu skóry szwem podnaskórkowym (grupa 2, n = 190). Zabieg obrzezania był wykonywany techniką *sleeve*. U wszystkich pacjentów zabieg przeprowadzono w znieczuleniu ogólnym, a po wprowadzeniu do znieczulenia zastosowano blokadę ogonową z użyciem lewobupiwakainy. Po starannym zapewnieniu hemostazy nacięcie było oczyszczone, a brzegi skóry zbliżone szwem podnaskórkowym. Następnie nakładano cienką warstwę kleju Glubran 2 i pozostawiono do wyschnięcia. Na żołędź i prącie nakładano maść z antybiotykiem.

Wyniki. Między obiema grupami nie zaobserwowano istotnych różnic dotyczących zapalenia, zakażenia rany, krwawienia, rozejścia się rany i obrzęku. Rezultat kosmetyczny i zadowolenie rodziców były lepsze w grupie 2.

Wnioski. Zastosowanie kleju Glubran 2 podczas obrzezania po zbliżeniu brzegów skóry szwem podnaskórkowym jest bezpieczne, wygodne i daje dobre rezultaty kosmetyczne (*Adv Clin Exp Med* 2009, 18, 4, 381–384).

Słowa kluczowe: obrzezanie, klej tkankowy.

Circumcision is one of the most common surgical procedures in the world [1]. It is a traditional and religious ceremony in Turkey, as in other Muslim countries, and in Jewish culture [2, 3].

Hemorrhage and infection are the most common complications of circumcision, followed by wound dehiscence, recurrent phimosis, preputial adhesions, trauma to the glans, and an ugly scar.

Traditional post-neonatal circumcision is performed using a standard sleeve technique with sutures for the approximation of the skin edges [4].

The use of tissue adhesives to seal wound sites where sutures would be inappropriate or unable to control bleeding is a widespread method in many open-surgical and endoscopic procedures, such as cardiovascular, thoracic, vascular, and abdominal surgery [5]. Glubran 2 is a tissue adhesive with high adhesive and hemostatic properties. It is a synthetic surgical glue consisting of N-butyl-2-cyanoacrylate (NBCA) modified by the addition of a monomer which allows obtaining an exothermic polymerization reaction at around 45°C with a slightly higher polymerization time than other cyanoacrylate glues [6, 7].

The advantages of tissue glue for approximating the skin edges during circumcision have been previously reported [1, 4, 8, 9]. The aim of this study was to evaluate the effects of the use of Glubran 2 on bleeding, wound healing, and patient comfort in the postoperative period together with its effectiveness in approximating the skin edges in circumcision.

Material and Methods

From January 2006 to April 2009, 247 healthy boys (age range: 1–12 years) admitted to the Abant Izzet Baysal University Medical Faculty underwent circumcision using suture for wound approximation (group 1, $n = 57$) or circumcision using subcuticular approximation and Glubran 2 (GEM s.r.l., Viareggio, Italy) for skin closure (group 2, $n = 190$). The parents were informed of the study and their consent was obtained. An identical surgical technique was performed by the same surgeon. All the patients received a standard anesthetic protocol including premedication with oral midazolam (0.5 mg/kg) 20–30 min preoperatively. The patients received either only caudal 0.25% plain levobupivacaine (1 ml/kg) or propofol in a dose of (3 mg/kg) intravenously if the patient had an intravenous line. An intravenous line was established in the other patients after inhalational induction with sevoflurane in stepwise incremental doses up to 6% *via* mask with 70% nitrous oxide in 30% oxygen. Infusion of Ringer's lactate at a rate of 10 ml/kg/h was started in both groups after induction. The patients were turned to the left lateral position as soon as anesthesia was sufficiently deep and an Epican-Paed caudal needle (Epican Braun, Melsongen, Germany) was inserted into the sacral hiatus under aseptic conditions. Anesthesia was later maintained with 2 mg/kg/h intravenous propofol infusion, allowing the child to breathe spontaneously, and oxygen was delivered (3 l/min) *via*

a simple face mask. Additional bolus doses of propofol were injected intravenously (0.5 mg/kg) as needed.

The circumcision was performed using a sleeve technique [10]. The skin was marked with a surgical pen to afford tension-free tissue closure. After freeing all adhesions between the glans and the prepuce, two hemostatic clamps were applied at the 12 o'clock aspect of the preputium. The preputium was cut between the clamps until the subcoronal groove was reached. Then, continuing using the scissors, the preputium was cut all around, taking care to leave a 5- to 10-mm-wide portion of the inner leaf of the prepuce all around below the corona. Hemostasis at the cut area was done using electrocautery and the bleeding of the frenular artery was clamped. In group 1, a 6–0 polyglactin suture was used for wound approximation and dressing was used. In group 2, the entire cut edges were approximated with a 6–0 polyglactin suture in a subcuticular manner and a thin layer of tissue glue was applied (Fig. 1A). To prevent the repair from adhering to the glans or penile shaft skin, antibiotic ointment was applied to these areas (Fig. 1B).

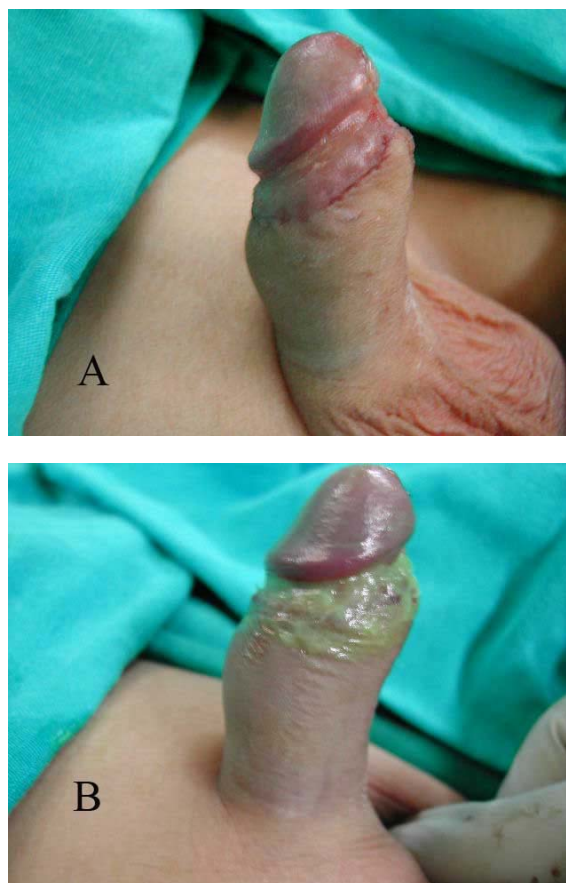


Fig. 1. Penis following tissue glue application (A). After antibiotic ointment application (B)

Ryc. 1. Prącie po nałożeniu kleju tkankowego (A). Prącie po nałożeniu maści z antybiotykiem (B)

In group 2, the patient’s diaper or underwear was replaced after extubation and transfer. No dressing was used in these cases and the patients were allowed to bathe according to their usual routine (after 48 hours) after discharge. All patients were evaluated in the office on days 1, 7, 15, and 30 postoperatively and again at 6 months to assess bleeding during the postoperative period, healing, inflammation, wound dehiscence, edema, cosmetic appearance (mild, good, excellent), and the parents’ satisfaction. The Mann-Whitney *U* and χ^2 tests were used to analyze the results. *P* values less than 0.05 were considered significant.

Results

There were no significant differences between the two groups regarding wound inflammation, wound infection, bleeding, wound dehiscence, and edema. The group 2 patients were comfortable and were able to move freely. Normal appearance was achieved within two weeks after the operation and the healing was good. At a mean follow-up period of 13 months (range: 2–18 months), no other complications occurred and the cosmetic appearance was good or excellent in all patients in group 2 (*p* < 0.005, Table 1). Parental satisfaction was also consistently great in group 2.

Table 1. Comparison of complications and cosmetic results in groups

Tabela 1. Porównanie powikłań i rezultatów kosmetycznych w grupach

	Group 1 (Grupa 1) (n = 57)	Group 2 (Grupa 2) (n = 190)	<i>P</i> -value
Complications (Powikłania)			
inflammation	1	0	> 0.05
infection	0	0	> 0.05
bleeding	3	0	> 0.05
wound dehiscence	0	0	> 0.05
edema	1	2	> 0.05
Cosmetic results – n, % (Rezultaty kosmetyczne – n, %)			
mild	29 (51)	10 (5)	
good	23 (40)	60 (32)	
excellent	5 (9)	120 (63)	< 0.0001*

* Statistically significant.

* Istotne statystycznie.

Discussion

Glubran 2 is a class III (for internal and external surgical use) medical-surgical product which fulfils the requirements of the European Directive on Medical Devices 93/42/EU and it has been approved for endoscopic use in Europe. Glubran 2 is largely used in laparoscopic and traditional surgery and in interventional radiology [11]. Indeed, it is diffusely applied on skin, eliminating the need for suture removal and providing good cosmetic results [6]. Glubran 2 is a straw-colored and clear liquid contained in 1-ml ready-to-use vials to be stored in a cool environment not exceeding +4°C. On contact with biological tissues in a moist environment, cyanoacrylate rapidly polymerizes to create a thin elastic film of high tensile strength, which guarantees firm adherence of tissues. The film easily tailors to the planes and tissues of application, is totally water resistant, and is not impaired by the presence of blood or organic fluids. When correctly applied, the glue begins solidification within 1 or 2 second and completes the process within 60 or 90 seconds. The glue reaches its maximum mechanical strength upon completion of this reaction [12].

Ozkan et al. [1] used N-butyl cyanoacrylate tissue glue for the mucocutaneous approximation of circumcision wounds in children and reported that the use of tissue glue in circumcision has no added advantage in inflammation, infection, bleeding, and dehiscence. However, it shortened operation time with a superior cosmetic result in that study, and for this reason they suggested that tissue glue approximation in circumcision is a feasible alternative. Subramaniam [9] found that circumcision closure with cyanoacrylate caused less pain and pain of a shorter duration than that with standard sutured closure. Finally, in a recent study involving 267 boys, Elmore et al. [4] made similar observations when two thin layers of 2-octyl cyanoacrylate were applied to the incision. They suggested that sutureless circumcision closure using 2-OCA is a safe, fast, and cosmetically appealing alternative to standard interrupted suture approximation.

Glue application may provide the chance of the patient using a diaper or the patient’s underwear in the early postoperative period, and the patients may take baths according to their usual routines (after 48 hours) after discharge. Wound dressing was not used in these cases, and this allows the patients to have a comfortable postoperative period and protects them from coming to the hospital for redressing of the wound, with the accompanying pain and psychological trauma of reopening the dressing. However, the main differ-

ence in our study from the other studies is that the edges were approximated with 6-0 polyglactin suture subcuticularly before applying the glue to

the skin. The authors concluded that this approach in circumcision is safe and comfortable for the patient, surgeon, and the anesthetist.

References

- [1] **Ozkan KU, Gonen M, Sahinkanat T, Resim S, Celik M:** Wound approximation with tissue glue in circumcision. *Int J Urol* 2005, 12, 374–377.
- [2] **Kavakli K, Nişli G, Özcan C, Avanoglu A, Ulman I, Polat A:** Safer and much cheaper circumcision using fibrin glue in severe hemophilia. *Haemophilia* 1997, 3, 209–211.
- [3] **Avanoglu A, Celik A, Ulman I, Ozcan C, Kavakli K, Nişli G, Gökdemir A:** Safer circumcision in patients with haemophilia: the use of fibrin glue for local haemostasis. *BJU Int* 1999, 83, 91–94.
- [4] **Elmore JM, Smith EA, Kirsch AJ:** Sutureless circumcision using 2-octyl cyanoacrylate (Dermabond): appraisal after 18-month experience. *Urology* 2007, 70, 803–806.
- [5] **Dickneite G, Metzner H, Pfeifer T, Kroez M, Witzke G:** A comparison of fibrin sealants in relation to their in vitro and in vivo properties. *Thromb Res* 2003, 112, 73–82.
- [6] **Kull S, Martinelli I, Briganti E, Losi P, Spiller D, Tonlorenzi S, Soldani G:** Glubran2 Surgical Glue: In vitro Evaluation of Adhesive and Mechanical Properties. *J Surg Res* 2009 Feb 25 [Epub ahead of print].
- [7] **Leonardi M, Barbara C, Simonetti L, Giardino R, Aldini NN, Fini M et al.:** Glubran 2: A new acrylic glue for neuroradiological endovascular use. *Intervent Neuroradiol* 2002, 8, 245–250.
- [8] **Arunachalam P:** A prospective comparison of tissue glue versus sutures for circumcision. *Pediatr Surg Int* 2003, 19, 18–19.
- [9] **Subramaniam R:** Sutureless circumcision: a prospective randomized controlled study. *Pediatr Surg Int* 2004, 20, 783–785.
- [10] *Text Atlas of Penile Surgery*, Daniel Yachia, Circumcision, p 21–28, Informa UK Ltd, London 2007.
- [11] **Montanaro L, Arciola CR, Cenni E, Ciapetti G, Savioli F, Filippini F, Barsanti:** Cytotoxicity, blood compatibility and antimicrobial activity of two cyanoacrylate glues for surgical use. *Biomaterials* 2001, 22, 59–66.
- [12] **Barillari P, Basso L, Larcinese A, Gozzo P, Indinnimeo M:** Cyanoacrylate glue in the treatment of ano-rectal fistulas. *Int J Colorectal Dis* 2006, 21, 791–794.

Address for correspondence:

Hayrettin Ozturk
Associate Professor of Pediatric Surgery
Abant Izzet Baysal University, Medical School
Department of Pediatric Surgery
14280 Bolu
Turkey
Tel.: +90 374-2534656 3220
E-mail: ozturkhayrettin@hotmail.com

Conflict of interest: None declared

Received: 16.06.2009

Revised: 30.06.2009

Accepted: 6.07.2009