

ORIGINAL PAPERS

Adv Clin Exp Med 2006, 15, 5, 843–849
ISSN 1230-025X

© Copyright by Silesian Piasts
University of Medicine in Wrocław

PAWEŁ REICHERT¹, ROMAN RUTOWSKI^{1, 2}, KRZYSZTOF ZIMMER¹, JERZY GOSK¹,
TOMASZ GRECZNER¹, KRZYSZTOF SKIBA¹, MONIKA KNAKIEWICZ¹

Treatment of Pseudoarthrosis of Long Bones with the Decortication Method Using Platelet-Derived Growth Factor

Leczenie stawów rzekomych kości długich metodą dekortykacji z użyciem płytkopochodnego czynnika wzrostu

¹ Chair and Clinic of Traumatology and Hand Surgery, Silesian Piasts University of Medicine in Wrocław, Poland

² Chair and Department of Sports Medicine, Wrocław University of Physical Education, Poland

Abstract

Background. Disturbances in the union of bone fractures, particularly in the form of pseudoarthrosis, are prolong the time of treatment, which has a measurable influence on costs and is also connected with serious difficulty and even invalidism of the patient. Despite considerable progress in the field, failures in the treatment of pseudoarthrosis are still the subject of studies and scientific descriptions in orthopedics and the traumatology of the movement organ. Many methods which assist in or stimulate the union processes as well as advances in methods of fracture stabilization are the result of these studies.

Objectives. Evaluating the results of treating pseudoarthrosis of the long-bone shafts of the arm by decortication, stable osteosynthesis using autogenic bone, implants, and platelet-derived growth factor (PDGF).

Material and Methods. Ten patients with pseudoarthrosis of long-bone shafts were treated by the decortication method using autogenic implants of spongy substance and platelet-derived growth factor in the years 2004 to 2005 at the Clinic of Traumatology and Hand Surgery of Silesian Piasts University of Medicine in Wrocław. Examination of the patients consisted of subjective and objective examinations as well as additional examinations (radiological, arteriographic, and scintiscanning). The Stewart and Hundley classification was employed in the clinical and subjective evaluation of the patient. To evaluate the control X-rays of the union, the radiological evaluation according to the division of Hammer was used. Intraoperative examination was documented with photographic pictures. The classification of Weber and Cech was used for classifying pseudoarthrosis.

Results. Bone union was observed in 9 of the 10 cases. Very good results were achieved in 5 patients, 3 patients finished therapy with a good result, and 1 with a satisfactory result. The mean time of achieving bone union was 4.6 months. Five patients achieved bone union after four months, 2 patients after five months, and 2 patients after 6 months.

Conclusions. Surgery with the decortication method using PDGF gives very good results in treating long-bone pseudoarthrosis. A faster time of achieving bone union was observed in patients treated with the decortication method with autogenic rich-platelet gel. Little bleeding and faster healing of the injury was observed (*Adv Clin Exp Med* 2006, 15, 5, 843–849).

Key words: pseudoarthrosis, nonunion, decortication, PDGF.

Streszczenie

Wprowadzenie. Zaburzenie wzrostu złamań kości, zwłaszcza w postaci stawu rzekomego, jest jednym z powikłań przedłużających czas leczenia, co ma wymierny wpływ na koszty, a także łączy się z poważnymi uciążliwościami, a nawet kalectwem chorego. Niepowodzenia w leczeniu stawów rzekomych, mimo znacznego postępu, nadal są przedmiotem badań i opracowań naukowych w ortopedii i traumatologii narządu ruchu. W pracy omówiono możliwość zastosowania metody jego leczenia – dekortykację z użyciem autogennych wszczepów istoty gąbczastej pobranej z talerza kości biodrowej oraz wykorzystaniem płytkopochodnego czynnika wzrostu.

Cel pracy. Ocena wyników leczenia stawów rzekomych trzonów kości długich kończyny górnej metodą dekor-

tykacji, stabilnej osteosyntezy, z użyciem autogennych wszczepów kostnych i płytkopochodnego czynnika wzrostu (PDGF).

Materiał i metody. W latach 2004–2005 w Klinice Chirurgii Urazowej i Chirurgii Urazowej AM we Wrocławiu leczono 10 chorych ze stawami rzekomymi trzonów kości długich kończyny górnej metodą dekortykacji z użyciem autogennych wszczepów istoty gąbczastej i żelu bogatopłytkowego. Diagnostykę stawów rzekomych oprócz standardowego badania radiologicznego poszerzono o badanie arteriograficzne i scyntygraficzne. Do klinicznej i subiektywnej oceny pacjenta zastosowano klasyfikację Stewarta i Hundleya. Do oceny kontrolnych rentgenogramów wykorzystano radiologiczną ocenę zrostu według podziału Hammera. Badanie śródoperacyjne udokumentowano zdjęciami fotograficznymi. Do klasyfikacji stawów rzekomych użyto klasyfikacji Webera i Cecha.

Wyniki. Zrost kostny uzyskano w 9 przypadkach, w skali Stewarta i Hundleya wynik bardzo dobry uzyskało 5 chorych, dobry 3, zadowalający 1. Średni czas uzyskania zrostu kostnego wynosił 4,6 miesiąca. U 5 chorych zrost osiągnięto po 4, u 2 po 5, u 2 po 6 miesiącach.

Wnioski. Operacja za pomocą metody dekortykacji z użyciem PDGF daje bardzo dobre wyniki w przypadku leczenia stawów rzekomych kości długich. Stwierdzono szybszy czas uzyskania zrostu kostnego w przypadku chorych leczonych metodą dekortykacji z użyciem autogennego żelu bogatopłytkowego. Stwierdzono mniejsze krwawienie i szybsze gojenie się rany (*Adv Clin Exp Med* 2006, 15, 5, 843–849).

Słowa kluczowe: staw rzekomy, brak zrostu, dekortykacja, płytkopochodny czynnik wzrostu (PDGF).

Disturbances in union of bone fractures, particularly in the form of pseudoarthrosis, prolongs treatment time, which has a measurable influence on costs and is also connected with serious difficulty and even invalidism of the patient. Despite considerable progress in the field, failures in the treatment of pseudoarthrosis are still the subject of studies and scientific descriptions in orthopedics and the traumatology of movement organ. Many methods which assist in or stimulate the union processes as well as advances in methods of fracture stabilization are the result of these studies. The possibilities of using decortication with autogenic implants of spongy substance taken from the iliac crest and with platelet-derived growth factor are discussed here.

We find the concept of pseudoarthrosis for the first time in the works of Malgaigne and Berdenheuer from the turn of the 19th to 20th centuries. Dunn [3] first introduced the concept of bone-osteoperiosteal-muscular decortication in 1936. Then in the 1960s, Forbes and Judet [4, 5] developed the idea. They both produced bone-osteoperiosteal-muscular flaps, and Forbes completed the decortication with spongy autogenic implants taken from the iliac crest in each case, while Judet used these implants only occasionally.

Platelet-derived growth factor (PDGF), found in granules of blood platelets, is a strong mitogen of mesenchymal cells which imposes mitogenic action on bone cells. This influences the *in vitro* proliferation, chemotaxis, and deposition of protein elements of matrix by osteoblasts [6] and the proliferation and differentiating of chondroblasts [7]. Considerable expression of PDGF (both of the proteins and of the mRNA encoding them as well as the receptors for PDGF) was observed in the places where cartilaginous and bone tissue appear as well as in the places of strong bone remodeling [8, 10]. It stimulates bone cells to produce DNA

and subsequent protein synthesis. In *in vivo* tests on rabbits, Nash and coworkers [9, 1] introduced PDGF into the crisis fissure and demonstrated its stimulating effect on the formation of callus and bone union. It was shown that PDGF also causes resorption of bone via stimulation of the synthesis of prostaglandins [8]. Growth factors, mainly PDGF, from a concentrate of blood platelets called plasma or rich-platelet gel, are released for 3–5 days after administration, accelerating the initial phases of healing. The blood platelet concentration in the preparation is $2\text{--}2.5 \times 10^6/\text{mm}^3$. PDGF was initially used in jaw and plastic surgery. Lately it has been gaining increasing popularity in orthopedics, particularly in filling bone defects, treating growth disturbances and difficult healing injuries, stabilizing the spine, and in the alloplasty of joints [1, 2]. The contemporary treatment of pseudoarthrosis includes both technical and biological aspects, collected in Table 1. When preparing the treatment plan it is necessary to decide upon the extent of the surgery and to choose the kind of stabilization. Moreover, it is necessary to remember pharmacological treatment and noninvasive methods which help bone union. Among the noninvasive methods which assist bone union are the possibilities of using magnetic fields, low-energy laser therapy, and ultrasound.

The treatment of long-bone pseudoarthrosis using the decortication method, stable osteosynthesis, and autogenic bone transplants using platelet-derived growth factor (PDGF) is an extension of tested methods and surgical technology with biological aspects accelerating bone union.

The purpose of this study was to evaluate the results of treating pseudoarthrosis of the long-bone shafts of the upper extremity with the method of decortication, stable osteosynthesis using autogenic bone, implants, and platelet-derived growth factor (PDGF).

Table 1. The treatment of pseudoarthrosis**Tabela 1.** Leczenie stawów rzekomych

- | |
|--|
| <p>1. Surgical debridement of pseudoarthrosis:</p> <ul style="list-style-type: none"> a) resection of pseudoarthrosis, b) bone-muscular decortication, c) restoring the marrow cavity. <p>2. Choice of stabilization of bone fragments:</p> <ul style="list-style-type: none"> a) stabilization of bone fragments: plate, screw, b) intramedullar nailing, c) use of external stabilizator, Zespol method. <p>3. Biological aspect accelerating healing of bone fractures can be achieved by:</p> <ul style="list-style-type: none"> a) local action: <ul style="list-style-type: none"> – osteogenic: autologous implants or transplants of bone, allogenic implants or transplants of bone, autologous transplants of marrow, – osteoconductive: calcic bone implants, calcic-collagen implants/composites, implants of bioactive glass, implants from bioactive polymers-osteconductive using a substance accelerating growth: TGF-β, BMP, aFGF and bFGF, PDGF, b) systemic action: <ul style="list-style-type: none"> – prostaglandin, – circulating osteogenic substances. |
|--|

Material and Methods

In the years 2004–2005, 10 patients with pseudoarthrosis of long-bone shafts were treated at the Clinic of Traumatology and Hand Surgery in Silesian Piasts University of Medicine in Wrocław with the method of decortication using autogenic implants of spongy substance and platelet-derived growth factor. The patients were initially treated surgically, the time from the fracture to decortication was 7 to 24 months, the treatment results were evaluated during control examinations, and observation was performed for 12 months from the date of decortication. The age of the patients ranged from 23 to 57 years, and 7 men and 3 women were operated on. Non-achievement of bone union during 12 months was classified as a poor result and the patient was qualified for further treatment.

Table 2. Classification of Stewart and Hundley [11]**Tabela 2.** Klasyfikacja Stewarta i Hundleya [11]

Result (Wynik)	Clinical evaluation (union, mobility of adjoining joints) (Ocena kliniczna)
Very good result (Bardzo dobry)	union, lack of pain, full mobility of adjoining joints
Good result (Dobry)	union, slight pain, limitation of mobility of adjoining joints less than 20 degrees, angular positioning of bone less than 10 degrees
Satisfactory result (Zadowolający)	union, periodical pain, limitation of mobility of adjoining joints between 20 and 40 degrees, angular positioning of bone over 10 degrees
Poor result (Zły)	lack of union, pathological mobility, continuous pain, limitation of mobility limitation of mobility of adjoining joints over 40 degrees, injury of radial nerve

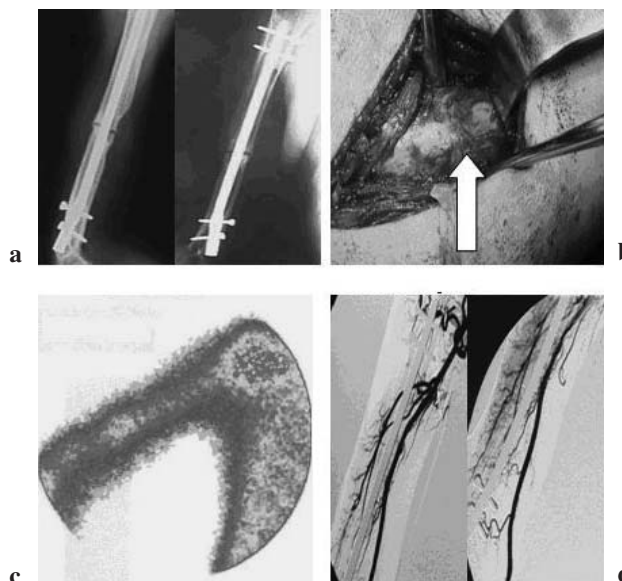


Fig. 1. Patient J.J., age 52, disease history no. 1276/04, oligotrophic joint. **a** – radiological image, **b** – intraoperative image: rounded bone fragments, **c** – bone scintiscan, **d** – arteriography

Ryc. 1. Chory J.J., lat 52, hist. chor. nr 1276/04, staw oligotroficzny. **a** – zdjęcie radiologiczne, **b** – zdjęcie śródoperacyjne – zaokrąglone fragmenty kostne, **c** – scyntygrafia, **d** – arteriografia

Examination of the patients consisted of subjective and objective examinations as well as additional examinations (radiological, arteriographic, and scintiscanning) (Figure 1). Radiological examination was based on the evaluation of X-rays made in two projections: anteroposterior and lateral. X-rays were taken of all patients operated on in the clinic before surgery, while qualifying for surgery, directly after the operation, and then during control examinations after 3, 4, 5, 6 and, in some cases, 9 and 12 months and after removal of the anastomosing connectors. The Stewart and Hundley classification was used in the clinical estimation and subjective estimation of the patient (Table 2) [11]. For evaluating control X-rays, the radiological evaluation of union according to the division of

Hammer was used (Table 3) [12]. Intraoperative examination was documented with photographic pictures. The classification of Weber and Cech was used to classify pseudoarthrosis [13].

All patients had oligotrophic pseudoarthrosis of the upper extremity bone. The autologous platelet concentrate preparation was administered intraoperatively in the amount of 5–10 ml. Classical decortication using autogenic implants of spongy substance taken from the iliac crest was performed in all patients. In 6 cases, intramedullary osteosynthesis was performed and in 4 patients osteosynthesis with the use of a plate was performed. Decortication and the application of PDGF are presented in Figures 2 and 3.

Results

Bone union was observed in 9 cases. Very good results were achieved in 5 patients, 3 patients finished therapy with good result, and 1 patient with a satisfactory result. In 1 case we did not obtain bone union. Figure 4 presents the result on the Stewart and Hundley scale.

The mean time of achieving bone union was 4.6 months. Five patients achieved bone union after four months, two after five months, and two patients after six months. The times of achieving bone union are presented in Figure 5. Examples of pseudoarthrosis, the course of bone union, and time of union achievement are shown in Figures 6 and 7. We observed little intraoperative bleeding, also from the ensuing surgical wound, and fast wound healing in all patients.

Table 3. Evaluation of union in Hammer's division [12]

Tabela 3. Ocena zrostu wg podziału Hammera [12]

Degree (Stopień)	Picture of callus (Obraz kostniny)	Pseudoarthrosis fissure (Szpara stawu rzekomego)	Union compactness (Zwartość zrostu)
1	homogenous bone structure	blurred	achieved
2	massive, bone trabeculation	hardly observable	achieved
3	bone bridge	observable	uncertain
4	trace, lack of bone bridge	clear	not achieved
5	lack of callus	clear	not achieved



Fig. 2. Procedure of decortication, **a** – obliterated marrow cavity, **b** – restored marrow cavity, **c** – spongy substance implants, **d** – covering of joint with spongy substance

Ryc. 2. Zabieg dekortykacji. **a** – zarośnięta jama szpikowa, **b** – udrożniona jama szpikowa, **c** – istota gąbczasta pobrana z talerza kości biodrowej, **d** – obłożenie stawu rzekomego istotą gąbczastą




Fig. 3. Applying PDGF: **a** into pseudoarthrosis fissure, **b** on spongy substance

Ryc. 3. Podaż PDGF: **a** do szpary stawu rzekomego, **b** do istoty gąbczastej

Discussion

Disturbances in bone union in connection with increased incidence of trauma become increasingly problematic in the contemporary traumatology of the movement organ. Not only medical difficulties in healing, but also the time in which it happens and, as a consequence, the treatment are the essential problems. According to Channely, practically all classic surgeries have already been worked out and all further changes will result only

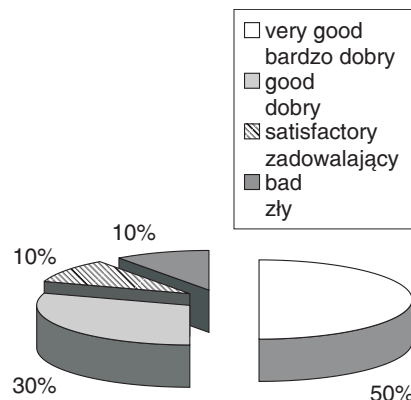


Fig. 4. Results of pseudoarthrosis treatment on Stewart and Hurdley scale

Ryc. 4. Wyniki leczenia stawów rzekomych w skali Stewarta i Hurdleya

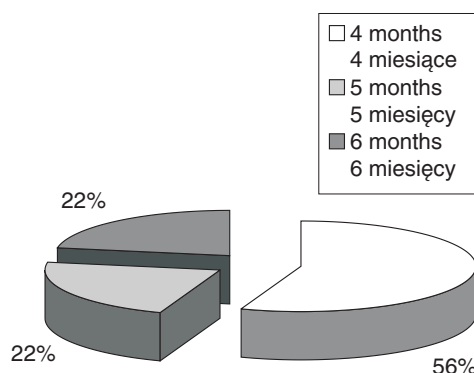


Fig. 5. Time of achieving bone union

Ryc. 5. Czas uzyskania zrostu kostnego

from modifications in the details of particular types of procedures until new methods enabling surgical interference in the process of osteogenesis are developed [2]. One of those methods is sup-

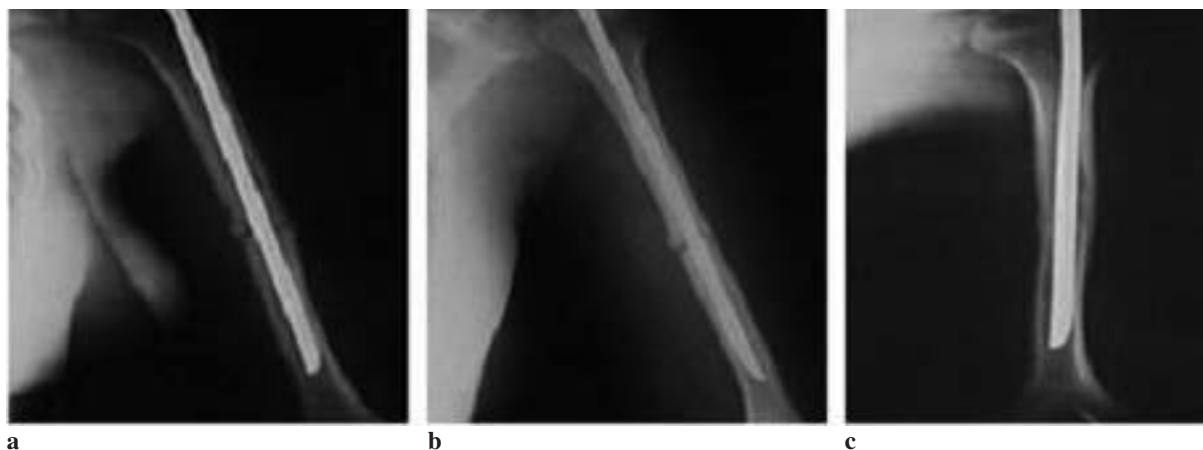

Fig. 6. Patient M. G., age 20, disease history no. 7761/04, humeral bone. **a** – time from fracture to surgery of decortication: 6 months, **b** – bone bridge after 3 months, **c** – bone union after 6 months

Ryc. 6. Chory M.G., lat 20, hist. chor. nr 7761/04, kość ramienna. **a** – czas od złamania do operacji dekortykacji – 6 miesięcy, **b** – most kostny po 3 miesiącach, **c** – zrost kostny po 6 miesiącach

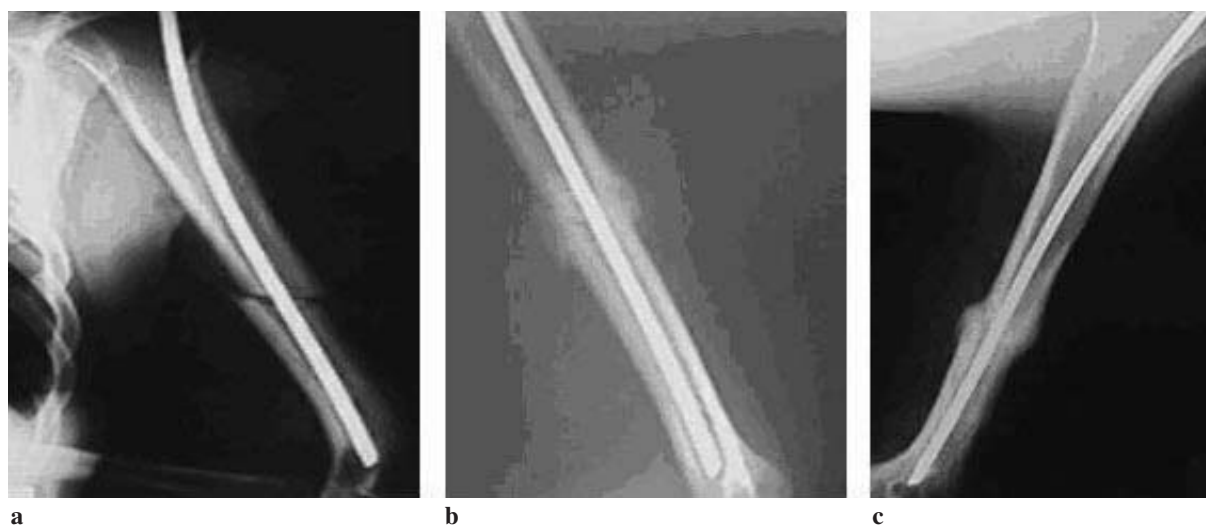


Fig. 7. Patient Z. R., age 25, disease history no. 459/05, humeral bone. **a** – time from fracture to surgery of decortication: 6 months, **b** – bone bridge after 3 months, **c** – bone union after 6 months

Ryc. 7. Chory Z. R., l. 25, hist. chor. nr 459/05, kość ramienna. **a** – czas od złamania do operacji dekortykacji – 6 miesięcy, **b** – most kostny po 3 miesiącach, **c** – zrost kostny po 6 miesiącach

plementing the classical method of decortication with the administration of growth factors.

The optimal course of bone union is conditioned by many factors, among which are patient age, general state, nutrition, and coexisting systemic diseases which can decrease, to a large extent, its rate. The most important part is ascribed to two factors: blood supply and the angiogenesis connected with it as well as immobilization. Angiogenesis is the key process coexisting with each kind of union or regeneration. It allows the restoration of the microcirculation-impaired injury, restoring correct tissue perfusion. Formation of the three-dimensional structure of vascular vessels is initiated by local lesions connected with the injury (vascular vessel injury and extravasation of morphotic elements of blood, activation of the coagulation system and fibrinolysis) causing local lesions (hypoxia and hypercapnia) and contributing to the appearance of a local inflammatory state [13, 14].

Albuminous growth factors released as the result of the cooperation of cellular elements of the peripheral blood and the walls of the injured vascular vessels and the elements of the extravascular matrix are mediators influencing the proliferation, migration, and differentiating of endothelial cells, leading to the formation of new vascularization [15]. Interactions between the endothelial cells of vascular vessels and bone cells constitute an important factor influencing the physiological changes [14]. Local vascularization is a decisive factor regulating the mineralization of growth cartilage [15].

Correct positioning of the fragments and their immobilization is another factor necessary for union formation [1, 2]. Displacement of the fragments greatly prolongs the time of return of extremity function, in some cases making the union process completely impossible. Ensuring the largest possible contact of the surface of the fractured bone fragments (optimally 80%) is, apart from correct immobilization, the basic task of the medical procedure. The percentage of very good and good results in treatment with the above method is comparable with those of other authors. The efficiency of the methods used, according to various authors, ranges from 62% in the case of Loitz [16–18] to 100% in the case of Forbes [4].

In the present study, bone union was achieved in 90% of cases. The time of achieving bone union was faster than in other studies. The time of achieving bone union in the upper extremity bones was from 4.5 months for Martinez [18] to 6.5 months for Elisabeth De Velde [19, 20]. This study has the character of a preliminary report, but it confirms the fact that growth factors have an essential influence on the course of bone union and can accelerate the time of achieving it. Admittedly, the disturbances in vascularization in the vicinity of pseudoarthrosis with accompanying injury to the brachial plexus in one patient was the cause of lack of union. This confirms the view that incorrect osteosynthesis or large defects in vascularization, that is the appearance of the angiogenesis process, are the main factors responsible for failures [1, 2].

References

- [1] **Górecki A:** Growth factors and bone tissue [Czynniki wzrostu i tkanka kostna]. *Oficyna Wydawnicza ASPRA-JR* 2004, 13–34, 72–80, 166, 241–259.
- [2] **Deszczyński J, Szczęsny G:** The process of bone union [Proces zrostu kości]. *Ortopedia Traumatologia Rehabilitacja* 2000, 3, 1–24.
- [3] **Dunn N:** Treatment of Ununited Fractures. *Br Med J* 1939, II, 221–223.
- [4] **Forbes DB:** Subcortical iliac bone grafts in fracture of the tibia. *J Bone Joint Surg* 1961, 43, 672–679.
- [5] **Judet R, Judet J, Orlandini J, Patel A:** La decortication osteomusculaire. *Rev Chir Orthop* 1967, 53, 43–63.
- [6] **Pfeifshifter J, Oechsner M, Naumann A, Gronwald RGK, Minne HW, Ziegler R:** Stimulation of bone matrix apposition in vitro by local growth factors: a comparison between insulin-like growth factor I, platelet-derived growth factor, and transforming growth factor β . *Endocrinology* 1990, 127, 69–75.
- [7] **Guerne PA, Blanco F, Kaelin A, Desgeorges A, Lotz M:** Growth factor responsiveness of human articular chondrocytes in aging and development. *Arthritis Rheum* 1995, 38, 960–968.
- [8] **Horner A, Bord S, Kemp P, Grainger D, Compston E:** Distribution of platelet-derived growth factor (PDGF) A chain mRNA, protein, and PDGF-a receptor in rapidly forming human bone. *Bone* 1996, 19, 353–362.
- [9] **Nash TJ, Howlett CR, Martin C, Steele J, Johnson KA, Hicklin DJ:** Effect of platelet-derived growth factor on tibial osteotomies in rabbits. *Bone* 1994, 15(2), 203–208.
- [10] **Canalis E, McCarthy T, Centrella M:** Growth factors and the regulation of bone remodelling. *J Clin Invest* 1988, 81, 277–288.
- [11] **Stewart MJ, Hundley JM:** Fractures of the humerus: a comparative study in methods treatment. *J Bone Joint Surg* 1995, 37, 681–692.
- [12] **Hammer R, Hammerby S, Lindholm B:** Accuracy of radiologic assessment of tibial shaft fracture union in humans. *Clin Orthop* 1985, 199, 233–238.
- [13] **Weber BG, Cech O:** Pseudoarthrosis, Pathophysiology, Biomechanics, Therapy, Results. New York–San Francisco–London. Grune and Stratton. Jovanovich Publishers 1976.
- [14] **Goldberg VM, Shaffer JW, Field G, Davy DT:** Biology of vascularized bone grafts. *Orthop Clin North Am* 1987, 18, 197–205.
- [15] **Winet H, Bao JY, Moffat R:** A control model for tibial cortex neovascularization in the bone chamber. *J Bone Miner Res* 1990, 5, 19–30.
- [16] **Rodriguez-Merchan EC, Forriol F:** Nonunion: general principles and experimental data. *Clin Orthop Relat Res* 2004, 419, 4–12.
- [17] **Lavini F, Brivio L:** Treatment of non-union of the humerus using the Orthofix external fixator. *Injury, J Care Injured* 2001 32, S-D-35-S-D-40.
- [18] **Martinez A, Herrera A, Cuenca J:** Marchetti nailing with decortication and bone graft in non-unions of the two upper thirds of the humerus. *Chirurgie de la Main* 2002, 21, 28–32.
- [19] **Velde E, van der Werken C:** Plate osteosynthesis for pseudoarthrosis of the humeral shaft. *Injury, Int. J Care Injured* 2001, 32, 621–624.
- [20] **Verbruggen J, Stapert J:** Failure of reamed nailing in humeral non-union: an analysis of 26 patients. *Injury, Int J Care Injured* 2005, 36, 430–438.

Address for correspondence:

Paweł Reichert
Klinika Chirurgii Urazowej i Chirurgii Ręki AM
ul. Traugutta 57/59
50-417 Wrocław
fax: +48 71 344 25 29
tel.: +48 75 744 92 68, tel: 601 40 74 93
e-mail: chiruraz@churaz.am.wroc.pl

Conflict of interest: None declared

Received: 10.05.2006

Revised: 11.07.2006

Accepted: 21.09.2006

Praca wpłynęła do Redakcji: 10.05.2006 r.

Po recenzji: 11.07.2006 r.

Zaakceptowano do druku: 21.09.2006 r.